

Shape Visualization of Dental Inclination in Class I and Bimaxillary Protrusion Malocclusions through Geometric Morphometric Analysis

Siti Balqish Oon¹, Aspalilah Alias², Sarah Haniza Abdul Ghani¹, Noraina Hafizan Norman¹

¹Centre of Paediatric Dentistry and Orthodontic Studies, Faculty of Dentistry, Universiti Teknologi MARA Sungai Buloh Campus, Jalan Hospital, 47000 Sungai Buloh, Selangor, Malaysia. ²Department of Basic Sciences and Oral Biology, Faculty of Dentistry, Universiti Sains Islam Malaysia, 55100 Kuala Lumpur, Malaysia.

Corresponding Author:
noraina@uitm.edu.my
Tel: +60361266458

Received: October 26, 2021
Accepted for publication: February 22, 2022.

ABSTRACT

Objectives: This study aimed to determine the shape of dental inclination between Class I malocclusion and bimaxillary protrusive Malay patients using geometric morphometric analysis obtained from lateral cephalometric radiographs. **Materials and Methods:** 128 Malay patients who met the inclusion criteria were recruited; of which 64 patients were in Class I malocclusion and another 64 patients in bimaxillary protrusion groups. Samples were in the age range of 18 to 40 years old, with a gender distribution of 41 males and 87 females. Pre-treatment orthodontic lateral cephalometric radiograph were traced and digitized. Thirteen landmarks of each radiograph were incorporated and converted into coordinates using TPSUtil software. The plots were then exported to MorphoJ Software for multiple Geometric Morphometric Analysis (GMA). **Results:** The results showed that there was a statistically significant difference ($p < 0.01$) in shape of dental inclination between the groups. Discriminant analysis and cross validation of these groups demonstrated 98% accuracy in identifying two types of dental malocclusion. The grid graphs illustrated the shape of dental inclination of the bimaxillary protrusion group as being significantly more proclined when compared to Class I malocclusion. **Conclusion:** This study concludes that the dissimilarities in dental inclination are identifiable in Class I malocclusion and bimaxillary protrusion and the shape differences can be visualized using geometric morphometric analysis.

Keywords: Class I, Bimaxillary Protrusion, Malocclusion, Geometric Morphometric Analysis (GMA).

INTRODUCTION

Malocclusion occurs when the size of upper and the lower jaws is not proportionate to one another that may lead to unaesthetic and abnormal bite patterns (Gruenbaum, 2010). The difference between the jaw and tooth size causes malocclusion such as crowding or tooth size arch length discrepancies. Malocclusion is the second most common dental disease among adults that impairs aesthetics and functional activities like chewing, speech, or imbalance of facial bones (Parmush & Mathur, 2002).

In 1964, Ballard and Wayman first described the Incisor classification (Ballad & Wayman, 1965). The incisor classification is based upon the relationship between the lower incisor edges and the cingulum plateau of the upper central incisors. Based on British standard institute's (1983) classification of malocclusion, it stated that for an incisor relationship to be classified as class I, the lower incisor edges preclude with or lie immediately below the cingulum plateau (middle part of the palatal surface) of the upper central incisors (BSCM, 1969).

Bimaxillary protrusion refers to a protrusive dentoalveolar position of maxillary and mandibular dental arches that produces a convex facial profile. It is often accompanied by various degrees of lip incompetence, mentalis strain, gummy smile, and anterior open bite (Chu, Bergeron & Chen, 2009). Bimaxillary protrusion is commonly found among ethnic groups such as in Malays, Asians in general and people of African American descent (Farrow, Kourosch & Khosrow, 1993; Lamberton, Reichart & Triratnanimit, 1980; Miura, Inoue & Suzuki, 1965). Many patients with bimaxillary protrusion seek orthodontic treatment to decrease the procumbency (Almutairi, Albarakati & Aldrees, 2015). Cephalometric parameters of bimaxillary protrusion is being defined, its prevalence of 37 per cent seen as high among orthodontic patients at UiTM (Othman et al., 2019). The prevalence in another study of skeletal and dental Class I bimax also showed relatively similar results ranging from 33 per cent and 40 per cent respectively (Razin et al., 2019).

Most clinicians classify bimaxillary protrusion as Angle Class I cases because of the class 1 molar relationship with good interdigitation and incisors present themselves as relatively normal in overjet and overbite.

Traditionally, the geometric morphometric method has been used to study the differences of species development in the field of biology. However, to date, it has been commonly used in several fields such as forensic anthropology, medicine, and dentistry to study human skeletal biology (Buck & Vijarsdo'ttir, 2004). Geometric morphometrics is a method based upon the Cartesian coordinates of landmarks and it is used to overcome the shortcomings of lateral cephalometric radiography (LCR) where it may not suffice as a detailed description of craniofacial morphology (Freudenthaler et al., 2016).

Therefore, the objective of this study is to determine the shape of dental inclination between Class I malocclusion and bimaxillary protrusive Malay patients using geometric morphometric analysis obtained from lateral cephalometric radiographs.

MATERIALS AND METHODS

This prospective study was conducted at two postgraduate orthodontic clinics in Faculty of Dentistry, Universiti Teknologi MARA (UiTM), namely the Sungai Buloh and Puncak Perdana campuses, in Selangor, Malaysia. Ethical approval was obtained from the UiTM Research Ethics Committee (REC/118/19) in May 2019. Records were taken from consented patients and were kept confidential. For the study eligibility, the following inclusion criteria were applied:

- i. Malaysian Malay with no interracial marriages in two generations predecessor.

- ii. aged between 18-40 years old.
- iii. patient presented with Class I malocclusion or Bimaxillary protrusion.

Any sample with dental anomalies such as hypodontia, caries or missing teeth and craniofacial anomalies or orthognathic surgery were excluded from this study. Sample size determination was performed using G power following rules for t-test means difference between two independent means (two group) with alpha significance level of 0.05 and power of 80%. Thus, the minimum selected sample size required for this study was 128. Patients' records were of 64 sample cephalometric radiographs grouped into Class I malocclusion and another 64 samples in bimaxillary protrusion. These pre-treatment orthodontic lateral cephalometric radiographs were traced and digitized. Thirteen landmarks in each radiograph were incorporated and converted into coordinates using TPSUtil software. (Rohlf, F.J. 2008. Tps util, file util program version 1.40). The thirteen landmarks and the definition of the landmarks are shown in Table 1.

The plots were then exported to MorphoJ Software (C. P. Klingenberg. 2011. MorphoJ: an integrated software package for geometric morphometrics used for multiple Geometric Morphometric Analyses (GMA) which included Generalized Procrustes Analysis (GPA), Principal Component Analysis (PCA), Discriminant Function Analysis (DFA), followed by Procrustes ANOVA to superimpose the shape of dental inclination between the groups and cross validation to classify the groups accordingly. All the landmarks were computed into wireframe and transformation grid graphs to illustrate and visualize their shape.

For error measurement, twenty radiographs were randomly selected, traced and digitized by 2 operators of orthodontic resident. Both operators had their radiographic tracings calibrated and approved by an orthodontic specialist. Tracings were then repeated randomly within 2 weeks interval to assess measurement error. The reliability assessment for consistency of cephalometric measurements among two operators, intraclass correlation coefficient (ICC), shows excellent agreement for both intra-operator (0.995) and inter-operator (0.991) assessment. The ICC gives a measure of reliability of the measurement in terms of consistency, with values between 0.75 to 1.00 as excellent correlation.

RESULTS

The results showed that there was a statistically significant difference ($P < 0.01$) in the shape of dental inclination between these two groups (Table 2). The discrimination result after cross validation of these groups demonstrated 98% accuracy in identifying the two dental malocclusions (Table 3). This means that, Discriminant Function Analysis has successfully distinguished specimens into their groups of malocclusion in the first phase (Figure 1). After cross-validation analysis from Discriminant Function Analysis, the variables were further analysed in the second phase for classification rate and the result showed that malocclusion was accurately classified at 98% using geometric morphometric analysis (Figure 2).

Wireframe and transformation grid graphs best distinguished shape characters between Class I and bimaxillary dental inclination. The grid graphs illustrated the shape of dental inclination of the bimaxillary protrusion group as being significantly more proclined when compared to Class I malocclusion (Figure 3).

Table 1: Cephalometric Landmarks and Description¹⁵.

Number	Landmark	Definition
1.	Sella (S)	The midpoint of the sella turcica (pituitary fossa)
2.	Nasion (N)	The most anterior point on the frontonasal suture in the midline
3.	Pogonion (Pog)	The most anterior point on the bony chin
4.	Menton (Me)	The most inferior point of the mandibular symphysis in the midline.
5.	Gonion (Go)	The most posterior and inferior point on the angle of the mandible.
6.	Anterior Nasal Spine (ANS)	The tip of the bony anterior nasal spine in the midline
7.	Posterior Nasal Spine (PNS)	The tip of the posterior nasal spine in the midline (located as a continuation of the base of the pterygopalatine fossa where it intersect with the nasal floor).
8.	Point A (Subspinale)	The deepest point on the curved profile of maxilla between the anterior nasal spine and alveolar crest.
9.	Point B (Supramentale)	The deepest point on the curved profile of the mandible between the chin and alveolar crest.
10.	Upper incisor Apex (UIA)	The root apex of the most anterior maxillary central incisor.
11.	Upper incisor Crown (UIC)	The crown of the most anterior maxillary central incisor.
12.	Lower incisor apex (LIA)	The root apex of the most anterior mandibular central incisor.
13.	Lower incisor Crown (LIC)	The crown of the most anterior mandibular central incisor.

Table 2: Procrustes ANOVA showed a significant difference of malocclusion in shape effect ($P < 0.01$).**

Effects	SS	MS	df	F	P-value
Shape	0.04	0.0004	22	9.72	0.001**

Table 3: The classification rate from Discriminant Function Analysis after cross-validation analysis.

Class I and Bimaxillary Protrusion	
Classification accuracy (Cross validation)	
Class I	100% (98%)
Bimaxillary Protrusion	98% (98%)

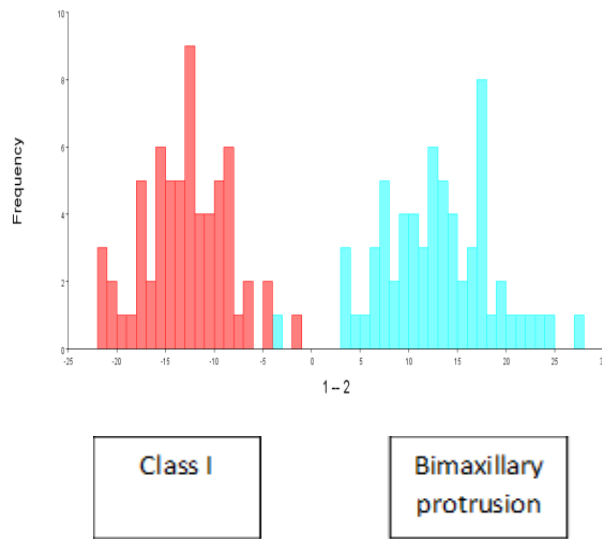


Figure 1: Discriminant Function Analysis: distinguished specimens into two groups.

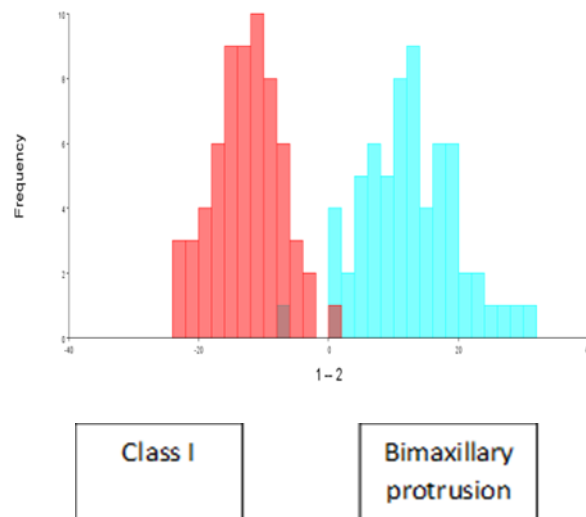


Figure 2: Discriminant Function Analysis: distinguished specimens into groups after cross validation

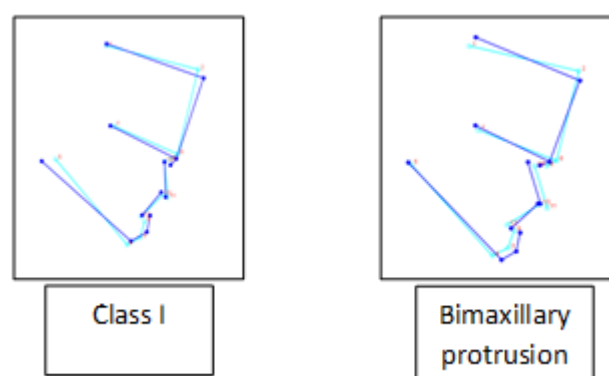


Figure 3: Wireframe and transformation grid graphs: Shape Characteristic.

DISCUSSION

The deviant size, shape, and inclination of the maxilla and mandible contribute to craniofacial variation and malocclusion (Fredeunthaler et al., 2016; Enlow, Kuroda & Lewis, 1971; Proffit & Fields, 1999). In the study performed by Fredeunthaler et al in 2016, found that by using geometric morphometric there is significant association between craniofacial shape and malocclusion (Fredeunthaler et al., 2016). In that study, the incisor position differed between malocclusion groups, where in Class III group, they found that the maxillary incisors are proclined and mandibular incisors are retroclined whereas in the Class II group, it showed of protruded mandibular incisors (Fredeunthaler et al., 2016). Apart from shape variation detection, Geometric Morphometric Analysis (GMA) permits a rigorous analysis of shape and size changes too (Singh, McNamara & Lozanoff, 2000). In the study performed by Singh et al in 2000, found that the shape change of Korean and European American mandible differed, where mandibular length was significantly greater in Korea Class III malocclusion patients (Singh, McNamara & Lozanoff, 2000).

Meanwhile, in our study we found that dental inclination between class I malocclusion and bimaxillary protrusion (bimax) groups are significantly different using this Geometric Morphometric Analysis (GMA) methods. These variables are identifiable and the two malocclusions were successfully classified and stratified to indicate their distinct differences in dental inclination. The bimax group had the incisors clearly shaped to be more proclined compared to Class I malocclusion. This finding is similar to Razin et al 2019, using cephalometric tracing digitization method, patients with this bidental protrusion displayed increased in upper and lower incisor proclination with resultant in an acute inter-incisal angle (Razin et al., 2019).

The discrimination function analysis is powerful in determining whether a set of landmark is effective in predicting inclusion to a category (Fredeunthaler et al., 2016). In this study, Discriminant Analysis and Cross validation showed accuracy of 98% of the dental inclination between Class I malocclusion and Bimaxillary Protrusion.

Geometric Morphometric Analysis (GMA) is regarded as a valid method of comprehensive shape assessment and evaluation of sample's homogeneity (Kouli et al., 2018; Bookstein, 1997; Halazonetis, 2004; Slice, 2007). This modern morphometric technique aid better understanding of the relationship between the size and shape of craniofacial features (Kimmerle, Ross & Slice, 2008). Our findings suggest that GMA can be used as a tool to tailor treatment planning of the malocclusion based on the craniofacial features of a patient's ethnicity within the population. GMA can be applied in orthodontic research to study growth, treatment effects, and shape variation (Fredeunthaler et al., 2016).

CONCLUSION

GMA can be applied in orthodontic research to study growth, treatment effects, and shape variation. It can be applied by dental students, academicians, researchers and practitioners as a quick reference and easy guide to tailor treatment planning of the malocclusion.

The dissimilarities in dental inclination are identifiable in Class I malocclusion and bimaxillary protrusion and the shape differences can be visualized using geometric morphometric analysis. This method is valid and reliable with the hope that it will benefit students, academicians, researchers, and patients.

DECLARATION OF INTEREST

The authors report no conflict of interest.

ACKNOWLEDGEMENT

We would like to thank to all the staff, radiologist, orthodontic postgraduate students in the Faculty of Dentistry, University Teknologi MARA for the kind assistance and facilitated our data collection procedure. We also would like to express our gratitude to University Teknologi MARA for giving us the opportunity to conduct the research.

REFERENCES

- Almutairi, T, Albarakati, S, Aldrees, A. Influence of bimaxillary protrusion on the perception of smile esthetics. *Saudi Medical Journal*. 2015;36(1):87–93.
- Ballard, C. F. and Wayman, J. B. A report on a survey of the orthodontic requirements of 310 army apprentices, *Transactions of the British Society for the Study of Orthodontics*, 86
- Bookstein, F.L. Landmark methods for forms without landmarks: morphometrics of group differences in outline shape. *Medical Image Analysis*, 1; 1997: 225–243 Lambertson, CM, Reichart, PA, Triratanimit, P. Bimaxillary protrusion as a pathologic problem in the Thai. *American Journal of Orthodontics*. 1980;77(3):320–9.
- British Standard Classification of Malocclusion (1969) BS4492 British Standard Institute, London.
- Buck, TJ, Vijarsdo'ttir, US. A proposed method for the identification of race in sub-adult skeletons: A geometric morphometric analysis of mandibular morphology. *Journal of Forensic Science*. 2004;49:1159–64.
- Chu, YM, Bergeron, L, Chen, YR. Bimaxillary protrusion: An overview of the surgical–orthodontic treatment. *Seminar Plastic Surgery*. 2009;23(1):32–9.
- Cobourne, M.T., & DiBiase, A.T. *Handbook of Orthodontics*, 2nd Edition, Elsevier; 2016:195
- Enlow DH, Kuroda T, Lewis AB. The morphological and morphogenetic basis for craniofacial form and pattern. *Am J Orthod*. 1971;41:161–88.

- Farrow, AL, Kouros Z, Khosrow, A. Bimaxillary protrusion in Black Americans – an esthetic evaluation and the treatment considerations. *American Journal of Orthodontics and Dentofacial Orthopedics*. 1993;104(3):240–50.
- Freudenthaler, J, Celar, A, Ritt, C, Mitterocker, P. Geometric morphometrics of different malocclusions in lateral skull radiographs. *Journal Orofacial Orthopedics*. 2016;78:11–20.
- Gruenbaum, T. Famous figures in dentistry mouth. *JASDA*. 2010;30(1):18.
- Halazonetis, D.J. Morphometrics for cephalometric diagnosis. *American Journal of Orthodontics and Dentofacial Orthopedics*; 2004: 125, 571–581
- Kimmerle, EH, Ross, A, Slice, D. Sexual dimorphism in America: Geometric morphometric analysis of the craniofacial region. *Journal of Forensic Sciences*. 2008;53(1):54–7.
- Koo TK, Li MY. A Guideline of Selecting and Reporting Intraclass Correlation Coefficients for Reliability Research. *J Chiropr Med*. 2016;15(2):155-63
- Kouli, A., Papagiannis, A., Konstantoni, N., Halazonetis, D. J., & Konstantonis, D. A geometric morphometric evaluation of hard and soft tissue profile changes in borderline extraction versus non-extraction patients. *European Journal of Orthodontics*;2018
- Lamberton, CM, Reichart, PA, Triratananimit, P. Bimaxillary protrusion as a pathologic problem in the Thai. *American Journal of Orthodontics*. 1980;77(3):320–9.
- Miura, F, Inoue, N, Suzuki, K. Cephalometric standards for Japanese according to the Steiner analysis. *American Journal of Orthodontics*. 1965;51:288–95.
- Othman, R.M., Koay, N.A.A., Ghani, S.H.A., Norman, N.H. Prevalence of Bimaxillary Protrusion Among UiTM Orthodontic Patients. *Compendium of Oral Science*, Vol, 6(1); 2019, 1-8.
- Parmesh, H, Mathur, VP. National oral health care program. *Indian Pediatrics*. 2002;39:1001–5.
- Proffit, WR, Fields, HW. *Contemporary Orthodontics*. 3rd ed. Mosby, St. Louis;1999:146–96.
- Razin, Siti Maisarah Ahmad, Ghani, Sarah Haniza Abdul, Norman, Noraina Hafizan. Bimaxillary Protrusion in Malay Population: Cephalometric Analysis of Skeletal, Dental and Soft Tissue Components. *Journal of International Dental and Medical Research* 2019: 203-211.
- Singh, G.D.,McNamara , J.A., and Lozanoff, S. Comparison of mandibular morphology in Korean and European-American children with Class III malocclusions using finite-element morphometry. *Journal of Orthodontics*. 2000;27:135–42.
- Slice, D.E. Geometric morphometrics. *Annual Review of Anthropology*; 2007: 36, 261–281