

Image Quality Optimization of Dental Panoramic Tomogram and Lateral Cephalogram: A Pilot Study on Human Skull

Liyana Ghazali¹, Mohd Yusmialdil Putera Mohd Yusof²,
Noraina Hafizan Norman^{3,*}

¹ Orthodontic Resident, Centre of Paediatric Dentistry and Orthodontic Studies,
Universiti Teknologi MARA (UiTM), Jalan Hospital,
47000 Sungai Buloh, Selangor, Malaysia

² Associate Professor, Centre of Centre of Oral & Maxillofacial Diagnostics and Medicine Studies,
Faculty of Dentistry, Universiti Teknologi MARA, Sungai Buloh, Selangor, Malaysia.

³ Orthodontist, Centre of Paediatric Dentistry and Orthodontic Studies,
Universiti Teknologi MARA (UiTM), Jalan Hospital, 47000 Sungai Buloh, Selangor, Malaysia

Corresponding Author:

noraina@uitm.edu.my

Handphone No.: +60124914707

Fax No: +603 6126 6458

Received: 23 March, 2020

Accepted for publication: 25 October 2020

DOI: <https://doi.org/10.24191/cos.v8i0.17482>

ABSTRACT

Purpose: The purpose of this study was to investigate the effects of varying scanning parameters of DPT and LC on diagnostic performance and quality of the images. **Materials and Methods:** Clinical evaluations of image quality were performed using an adult human skull with permanent dentition. Dental panoramic tomogram (DPT) and lateral cephalogram (LC) images were obtained using two different radiographic machines Instrumentarium 300OP taken at Sungai Buloh (SB) and Sirona Orthophos 3D taken at Puncak Perdana (PP) by varying tube voltages. Two orthodontic residents assessed images based on overall quality using a five-point rating scale and diagnostic performance by detection of anatomical landmarks. The correlations between radiation doses and diagnostic value of the images were analyzed using Pearson's Correlation Test. Univariate analysis was calculated for the evaluation for image quality. Intra-class Correlation Coefficient (ICC) was used to test for intra-rater and inter-rater reliability. **Results:** Both modalities taken at both centers showed negative correlation between dosage and detection of anatomical landmarks except for LC SB. All images were rated at least with median of 3= more than adequately presented regardless of the radiation dosage except for DPT PP (median 5= inadequately presented). **Conclusion:** Lower dosage parameters should be used when taking DPT and LC as images appeared darker, lower in quality and less anatomical landmarks can be detected at higher scanning parameter.

Keyword: dose reduction, dental radiography, image quality, diagnostic performance

Abbreviations: Dental panoramic tomogram (DPT), lateral cephalogram (LC), Sungai Buloh (SB), Puncak Perdana (PP)



INTRODUCTION

Dental panoramic tomogram (DPT) is a very popular technique with more than 2 million views taken per year in UK alone (Murray, Diane, 2002). It is due to its quick and relatively simple procedure (Rushton and Horner, 1996). In orthodontics, DPT is essential to give the general information about the anatomy of maxilla and mandible for example erupted and unerupted teeth, the root formation, suggestion of carious teeth, periapical pathology, general bone condition or any presence of impacted or supernumerary teeth. Image quality and diagnostic value of the images is absolutely critical to ensure that all information needed for diagnosis and treatment planning are not obscured.

Lateral cephalogram (LC) since its introduction by Broadbent in 1926, has become a standard assessment tool in orthodontics (Broadbent B Sr, Broadbent B Jr, 1975; Devereux *et al.*, 2011). Lateral cephalogram is indicated when functional and fixed appliances to be used in patients with skeletal discrepancy, for teaching purposes in patients with moderate skeletal discrepancies, to assess the location and assessment of unerupted, malformed or ectopic teeth, for assessing growth and planning orthodontic-orthognathic surgery (Isaacson, Thom, Atack & Horner, 2015).

Despite the need and indications of the radiograph in dental practice, International Commission on Radiological Protection (ICRP) has outlined the optimization principle in patient exposure to ensure that the exposure to radiation is kept as low as reasonably achievable (ALARA) (ICRP, 2007). With increasing use of radiographs for orthodontic diagnostic and treatment planning, particularly DPT and LC has raised concern about radiation risks particularly somatic stochastic effect (Whaites E, 1992; Devereux *et al.*, 2011). Radiation exposure increases the risk of cancer throughout life and the dose-response relation for cancer at low doses is assumed to be linear without threshold (Kamiya *et al.*, 2015).

By using digital modalities, it is possible to provide low radiation dose (Murray, Diane, 2002) by means of adjustments variables on radiographic machines; tube potential (kV), tube current (mA) and time of exposure (seconds). However, this should not result in a significant drop in image quality and the diagnostic performance of the images. The challenge in optimization of DPT and LC is to decrease radiation dose without drastically reducing the diagnostic value and quality of the images. Due to variety of scanning parameters between different types and manufacturers, such approach require machine- specific examinations. Thus, this study was conducted to investigate the effects of varying scanning parameters of DPT and LC of different radiographic machines on diagnostic performance and quality of the images.

MATERIALS AND METHODS

Ethical Consideration

The ethics for this study was obtained from UiTM Ethics Research Committee in July 2017. This study was conducted in accordance to the ICH Good Clinical Practice Guidelines and the Declaration of Helsinki.

Study Design and Sampling

This study was conducted using a cross- sectional study design with convenient sampling method. The sample size included different variations of the scanning parameters on the radiographic machine. There were 35 DPT (60-73 kV, 3.2- 13 mA) and 6 LC (85- 90 kV, 8.0- 13 mA) taken using Orthopantomograph® OP300 (Instrumentarium DENTAL, Finland) at Sungai Buloh (SB) and 16 DPT (60- 90 kV, 10- 16mA) and 16 LC (60- 90 kV, 9- 16mA) were captured using Sirona Orthophos 3D (Denstply, USA). The time of exposure remained constant throughout the procedures.

Image Acquisition

An adult human skull with dentition was positioned upright to ensure the stabilization of mid sagittal plane and Frankfort plane using indicating light beam (Hofmann *et al.*, 2016). All radiographic acquisition procedures were performed by a single operator to reduce inter- operator variability.

Image Evaluation

All images were saved in JPEG digital format and were displayed on LENOVO Ideapad 310 with 14.0” HD LED (2685 x 2235 resolution) for image assessment and evaluation. All other setting of contrast and brightness were kept constant at 80% and all images were viewed in dark room to increase visibility. All images were blinded and randomized by a central trial coordinator. Prior to image assessments, a calibration process was conducted for the assessors who have more than seven years clinical experience. All images were assessed 3 times at separate occasions by first assessor for intra-rater reliability assessment (Houston, 1983). Ten images from each modality were randomly selected using digital generator and assessed by a second assessor to determine inter-rater reliability.

Treatment Outcome

There were two outcomes that were assessed in this clinical trial: diagnostic performance and image quality. For assessment of diagnostic performance, anatomical landmarks on dental panoramic tomograms and lateral cephalogram were scored based on Table 1 (Maeda *et al.*, 2018) and Table 2 (Durão *et al.*, 2015) as being presented or not . All images were scored for overall image quality based on a five-point rating scale; 1= excellent, 2= more than adequately presented, 3= adequately presented, 4= barely adequately presented, 5= inadequately presented (Dannewitz *et al.*, 2002).

Table 1: Anatomical landmarks on DPT

Region	Anatomical Landmarks
Maxilla	Anterior nasal spine
	Nasal septum
	Inferior concha
	Right and Left maxillary tuberosity
	Right and Left maxillary sinus
	Right and Left floor of maxillary sinus
	Right and Left zygomatic arch
	Right and left zygomatic bone
	Articular eminence
	Periapical of tooth 13
	Periodontal ligament space of tooth 26
	Pterygopalatine fossa
Mandible	Periapical of tooth 37

Periodontal ligament space of tooth 46
Styloid process
External auditory meatus
Disc space
Dentino-enamel junction of 46
Right and Left mandibular canal
Right and Left mental foramen
Trabecular structure of mandibular horizontal ramus
Right and left condylar head
Right and Left coronoid processes
External oblique ridge

Table 2: Anatomical landmarks on LC

No	Anatomical Landmarks
1	Sella (S)
2	Nasion (N)
3	Orbitale (Or)
4	Porion (Po)
5	Anterior Nasal Spine (ANS)
6	Posterior Nasal Spine (PNS)
7	A point
8	B point
9	Pogonion (Pog)
10	Menton (Me)
11	Gonion (Go)
12	Condylion
13	Articulare (Ar)
14	Nasale

15	Basion
16	Gnathion
17	Incision inferius
18	Root apex of lower incisor
19	Root apex of upper incisor
20	Incision superius
21	Pterygopalatine Fossa

Statistical Analysis

Statistical analysis was conducted using SPSS version 23.0 (SPSS Inc. Chicago IL). Univariate analysis was performed for the image quality assessment and reported as median and inter-quartile range (IQR). The relationship between dose of radiation and detection of anatomical landmarks was demonstrated using Pearson's Correlation. All statistical tests were interpreted at 5% significance level. The intra- and inter-rater agreements were calculated using Intraclass Correlation Coefficient (ICC).

RESULTS

For evaluation of diagnostic performance, Table 3 showed that there were negative correlations between detection of anatomical landmarks and radiation dose for DPT taken at both centers and LC PP. These results indicated that when there was increase in radiation dose, less anatomical landmarks can be detected on the images. For LC taken at SB, there was a fair correlation between scores of detections of anatomical landmarks and radiation dose. All results were found to be statistically insignificant except for DPT PP ($p < 0.001$).

Table 3: Pearson's Correlation between radiation dose and score of anatomical landmarks on DPT

Components	Pearson's Correlation (r)	p- value	Description
DPT SB	-0.128	0.464	Negative
LC SB	0.452	0.368	Fair
DPT PP	-0.918	0.000*	Negative
LC PP	-0.147	0.602	Negative

*Correlation is significant at the level of 2-tailed ($p < 0.05$)

For image quality assessment, all images showed adequately presented images with median score of 3.0 except for DPT PP where the median score was 5.0 (inadequately presented) (Figure 1 a-d). The examples of DPT and LC taken using different scanning parameters were shown in Figure 2 (a-c) and Figure 3 (a-c).

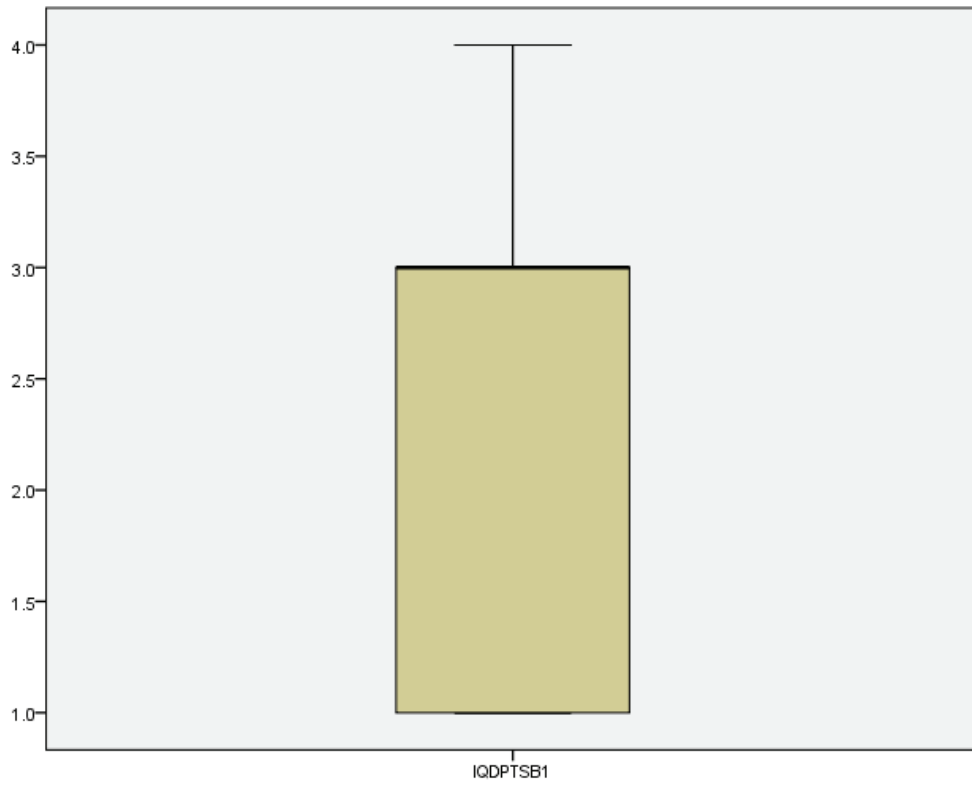


Figure 1a: Boxplot diagram showing the range of scores for image quality of DPT SB with median score of 3.0 (IQR 2.0).

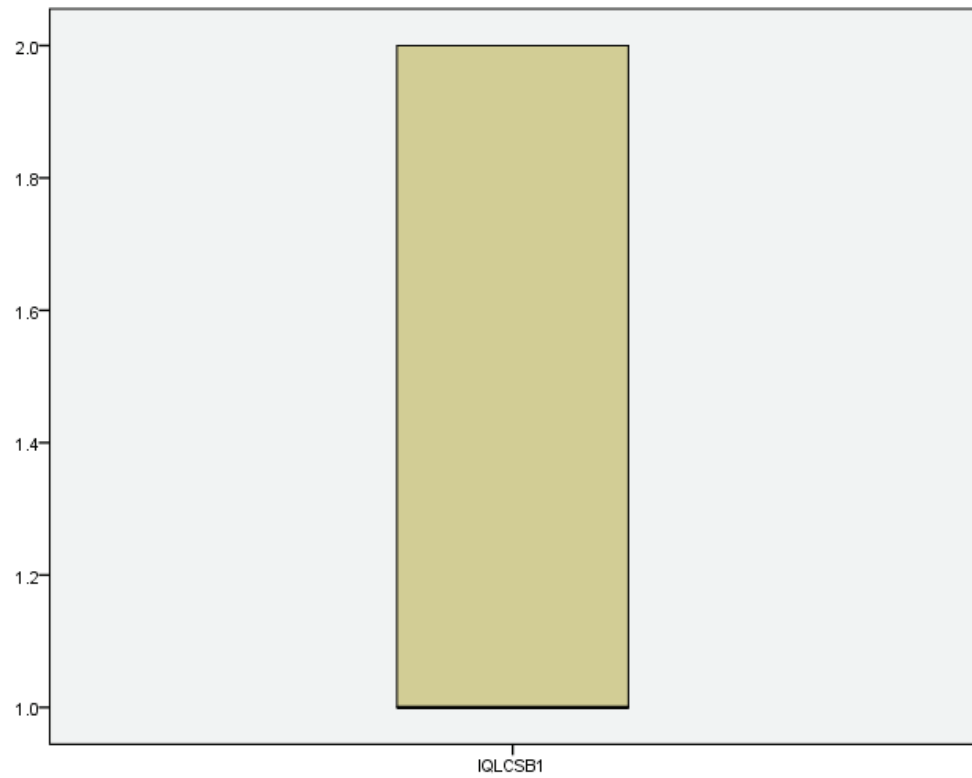


Figure 1b: Boxplot diagram showing the range of scores for image quality of LC SB with median score of 1.0 (IQR 1.0).

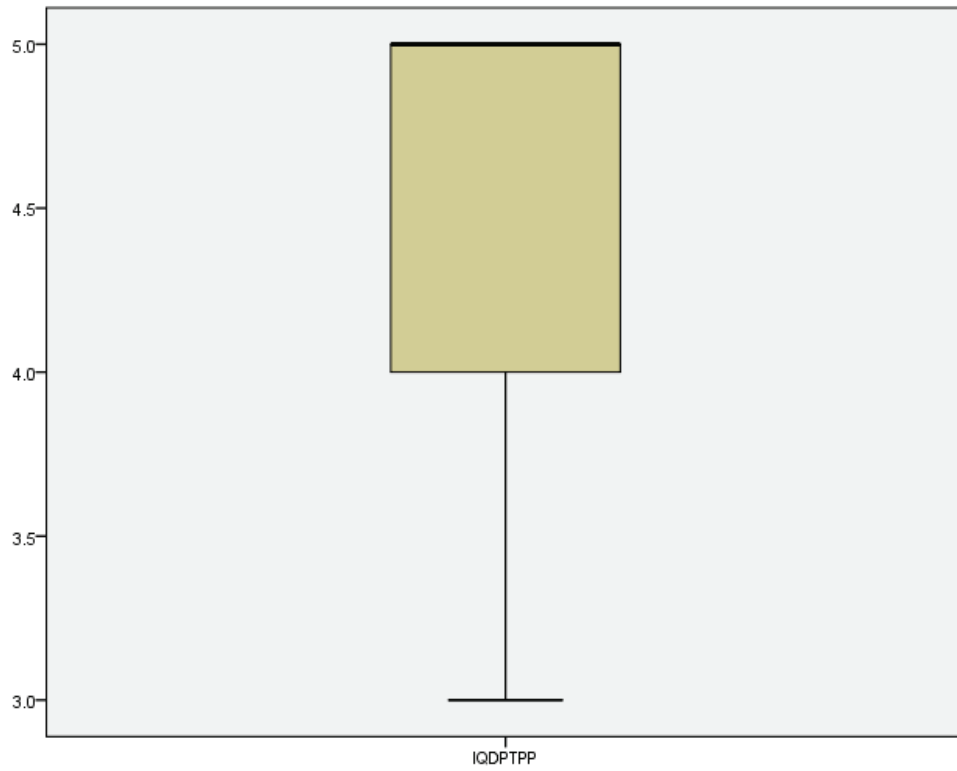


Figure 1c: Boxplot diagram showing the range of scores for image quality of DPT PP with median of 5.0 (IQR 1.0).

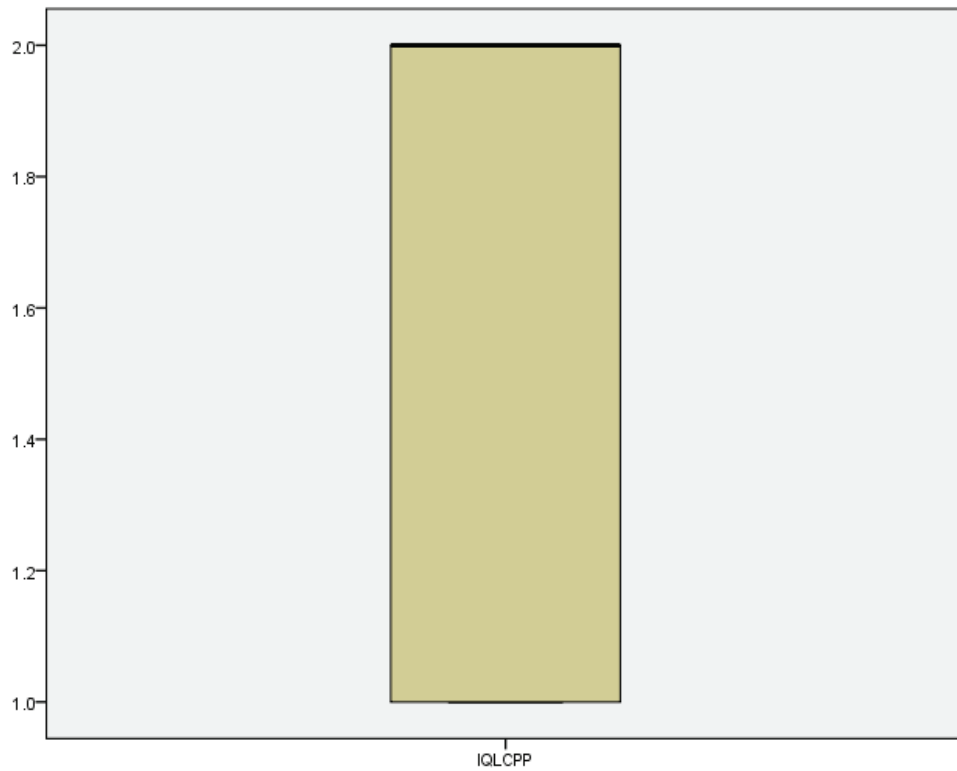


Figure 1d: Boxplot diagram showing the range of scores for image quality of LC PP with median of 2.0 (IQR 1.0).

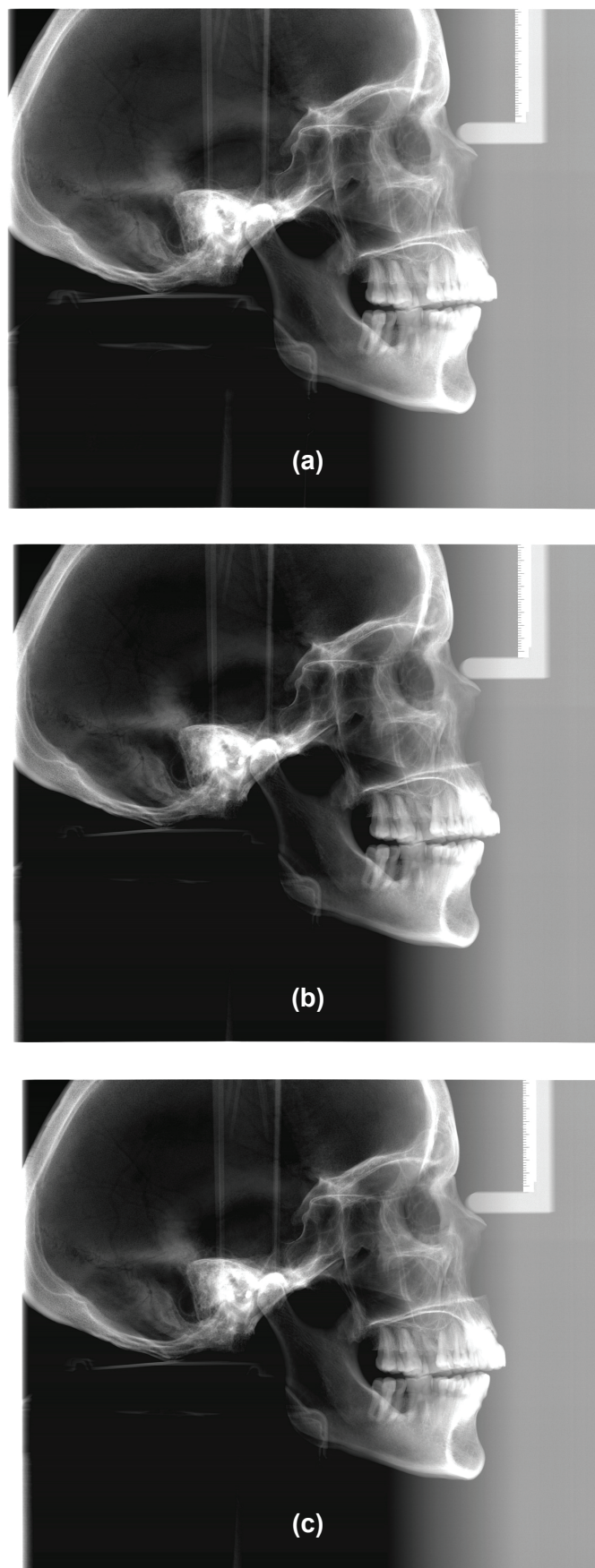
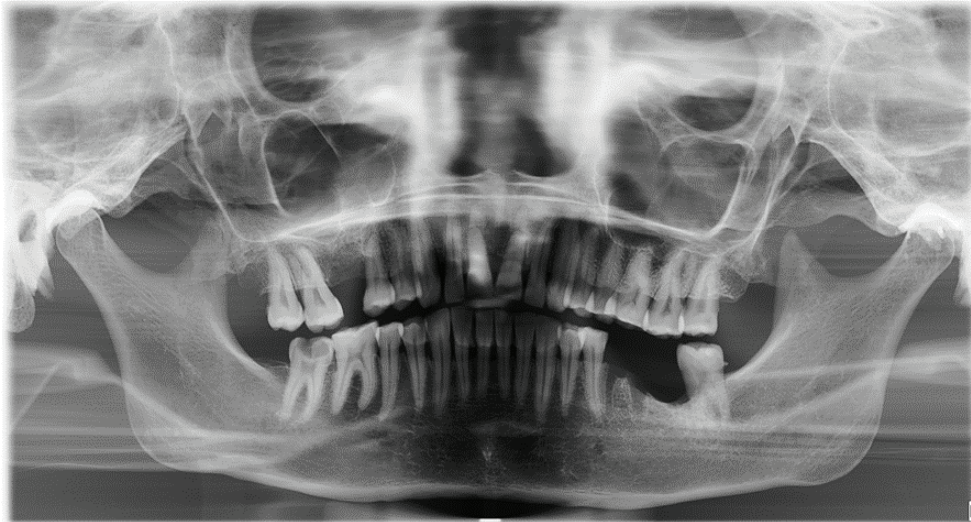
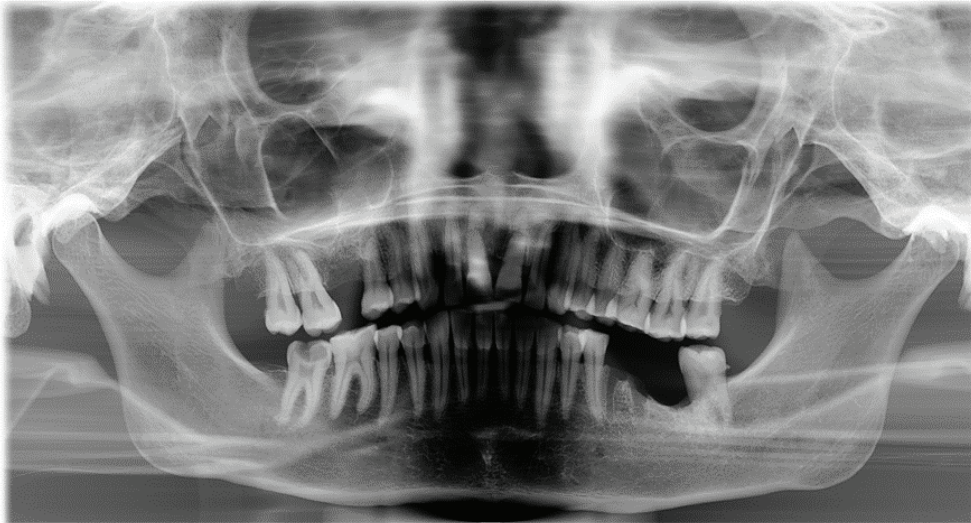


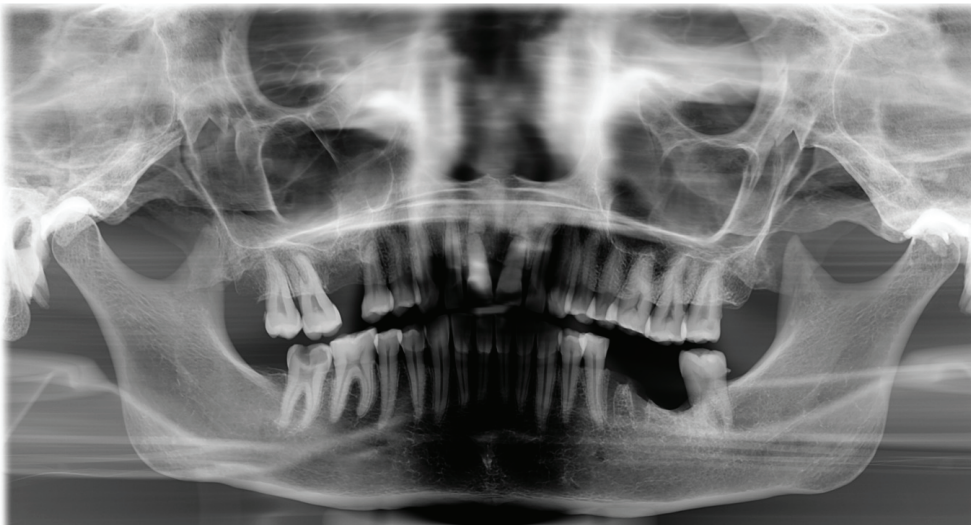Figure 2: LC taken with different scanning parameters a) 85kV, 8mA b) 85kV, 10mA c) 85kV, 13mA



(a)



(b)



(c)

Figure 3: DPT taken with different scanning parameters a) 60kV, 3.2mA b) 66kV, 6mA c) 70kV, 8mA

DISCUSSION

The concept of optimization as defined International Commission on Radiological Protection (ICRP) as the source- related process in order to keep the magnitude of radiation doses, the number of people exposed and the likelihood of potential exposure as low as reasonably achievable (ALARA) (ICRP, 2007). Since the radiation is cumulative, health professional must limit radiation exposure to the absolute minimum and radiographic examination and exposure must be optimal and justifiable (Tanner *et al*, 2000). According to general rule of radiation protection, the indications for exposure of dental panoramic tomogram and lateral cephalogram must be reviewed and approved by clinician in charge in order to avoid any unnecessary exposure to patients(Isaacson, Thom, Atack & Horner, 2015). This is very important to minimize stochastic effect of radiation that can lead to cell changes and mutations (Ribeiro and Angelieri, 2008).

In the current study, negative correlations between scores of detections of anatomical landmarks and radiation doses because at higher doses, images appeared darker thus less anatomical landmarks can be scored. This is particularly true especially for DPT PP using Sirona Orthophos 3D when the result was found to be statistically significant. Thus, the optimal value for each radiographic modality must carefully be tested and selected based on physical characteristics of the patient and the specific diagnostic imaging task (Huda and Abrahams, 2015). A contradicting result of LC SB taken using Instrumentarium 300 OP indicates that more anatomical landmarks can be detected when the doses increases. This fair correlation might be due to limited variation of the parameters as there were only six combinations of tube potential and tube current available on the machine.

For image quality assessment, all the images except DPT PP were adequately presented with median score of 3.0. This finding was supported by previous studies by (Dannewitz *et al.*, 2002; Kaeppler, Dietz and Reinert, 2006; Alkurt *et al.*, 2008) when they found that there was no significant differences of scores of image quality when radiation doses were reduced. In contrast, DPT PP images were found to be inadequately presented with median score of 5.0. This is because as tube potential increases, contrast of the images will reduce causing the images to appear darker and poorly presented (Brindhaban *et al.*, 2005). This is correlated with evaluation of diagnostic performance which resulted in significantly less detection of anatomical landmarks when the radiation doses increase ($p<0.001$).

CONCLUSION

In conclusion, when radiation dose increases by increasing the dose parameters of digital dental panoramic tomogram and lateral cephalogram, less anatomical landmarks can be detected thus reducing the diagnostic performance of the images.

ACKNOWLEDGEMENT

No financial interest.

REFERENCES

- Alkurt, M. T. *et al.* (2008). 'Clinical evaluation of dose reduction on image quality of panoramic radiographs', *Journal of Contemporary Dental Practice*, 9(5), pp. 034–041.
- Brindhaban, A. *et al.* (2005). 'Effect of x-ray tube potential on image quality and patient dose for lumbar spine computed radiography examinations', *Australasian Coll. of Phys. Scientists and Engineers*, 28(4), pp. 216–222. doi: 10.1007/BF03178721.
- Broadbend B Sr, Broadbent B Jr, Golden. W. *Bolton standards of dentofacial development growth*. St. Louis: Mosby (1975).
- Dannewitz, B. *et al.* (2002). 'Effect of dose reduction in digital dental panoramic radiography on image quality', *Dentomaxillofacial Radiology*, 31(1), pp. 50–55. doi: 10.1038/sj.dmfr.4600651.
- Devereux, L. *et al.* (2011). 'How important are lateral cephalometric radiographs in orthodontic treatment planning?', *American Journal of Orthodontics and Dentofacial Orthopedics*, 139(2), pp. e175–e181. doi: 10.1016/j.ajodo.2010.09.021.
- Durão, A. P. R. *et al.* (2015). 'Cephalometric landmark variability among orthodontists and dentomaxillofacial radiologists: A comparative study', *Imaging Science in Dentistry*, 45(4), pp. 213–220. doi: 10.5624/isd.2015.45.4.213.
- E, Whaites. *Essentials of dental radiography and radiology*. Edinburgh, United Kingdom: Churchill Livingstone (1992).
- Hofmann, E. *et al.* (2016). 'Landmarks of the Frankfort horizontal plane: Reliability in a three-dimensional Cartesian coordinate system', *Journal of Orofacial Orthopedics*, 77(5), pp. 373–383. doi: 10.1007/s00056-016-0045-1.
- Houston, W. J. B. (1983). 'The analysis of errors in orthodontic measurements', *American Journal of Orthodontics*, 83(5), pp. 382–390. doi: 10.1016/0002-9416(83)90322-6.
- Huda, W. and Abrahams, R. B. (2015). 'Radiographic Techniques, Contrast, and Noise in X-Ray Imaging', *American Journal of Roentgenology*, 204(2), pp. W126–W131. doi: 10.2214/AJR.14.13116.
- ICRP PUBLICATION 103 (2007). 'The 2007 Recommendations of the International Commission on Radiological Protection', *The International Commission on Radiological Protection*, 37, pp. 1–332. doi: <https://doi.org/10.1016/j.icrp.2007.10.001>.
- Isaacson KG, Thom AR, Atack NE, Horner K, W. E. (2015). 'Guidelines For The Use of Radiographs In Clinical Orthodontics', *British Orthodontic Society*, 4th Editio. Available at: [https://www.bos.org.uk/Portals/0/Public/docs/General Guidance/Orthodontic Radiographs 2016 - 2.pdf](https://www.bos.org.uk/Portals/0/Public/docs/General%20Guidance/Orthodontic%20Radiographs%202016%20-%202.pdf).
- Kaeppler, G., Dietz, K. and Reinert, S. (2006). 'The effect of dose reduction on the detection of anatomical structures on panoramic radiographs', *Dentomaxillofacial Radiology*, 35(4), pp. 271–277. doi: 10.1259/dmfr/16653683.
- Kamiya, K. *et al.* (2015). 'Long-term effects of radiation exposure on health', *The Lancet* pp. 469–478. doi: 10.1016/S0140-6736(15)61167-9.
- Maeda, N. *et al.* (2018). 'Dental students' levels of understanding normal panoramic anatomy', *Journal of Dental Sciences*, 13(4), pp. 374–377. doi: 10.1016/j.jds.2018.08.002.

- Murray, Diane, W. A. (2002). 'Review Dental Panoramic Tomography : What the General Radiologist Needs to Know', *Clinical Radiology*, 61, pp. 1–7. doi: 10.1053/crad.2001.0826.
- Ribeiro, D. A. and Angelieri, F. (2008). 'Cytogenetic biomonitoring of oral mucosa cells from adults exposed to dental X-rays', *Radiation Medicine - Medical Imaging and Radiation Oncology*, 26(6), pp. 325–330. doi: 10.1007/s11604-008-0232-0.
- Rushton, V. E. and Horner, K. (1996). 'The use of panoramic radiology in dental practice', *Journal of Dentistry*, 24(3), pp. 185–201. doi: 10.1016/0300-5712(95)00055-0.
- Tanner, R. J. and Great Britain. National Radiological Protection Board. (2000). *Frequency of medical and dental x-ray examinations in the UK--1997/98*. National Radiological Protection Board.