

Original Article

Selective Occlusal Features of Primary Dentition in Malay Children at a Centre in Sungai Buloh

Fathinah Hanem Azamzaki¹, Nurhanis Baharuddin¹, Shobha Tandon¹, Annapurny Venkiteswaran^{*,1}

¹ Faculty of Dentistry, Universiti Teknologi MARA, Sungai Buloh Campus, Jalan Hospital, 47000 Sungai Buloh, Selangor, Malaysia.

DOI: <https://doi.org/10.24191/cos.v5i0.17504>

Abstract

Objectives: To determine the different occlusal characteristics in primary dentition of 3 to 6 year old Malay children and to create a preliminary database for future Malaysian studies as currently none of the studies has been conducted in Malaysian population regarding the occlusal features in primary dentition.

Materials and method: The subjects were within the age ranging from 3 – 6 years old attending nurseries and kindergartens located within Sungai Buloh, Selangor. Sixty subjects were screened but only 47 fulfilled the criteria to be included in this study. Intra-oral examination was done to determine the terminal plane, canine relationship, overjet, overbite and primate space in the subjects.

Results: Almost two thirds of the subjects (72.34%) presented with straight terminal plane. All but one subject were observed with Class I canine relationship. 61.7% subjects were with an ideal overjet and 53.19% of subjects had an ideal overbite. The mean value for primate space in the maxilla was 2.92mm and 1.60mm in the mandible. There was no significant difference between gender in all the parameters assessed.

Conclusion: The results from the study shown that only few of the subjects had a tendency of malocclusion in their permanent dentition. However, a longitudinal study should be done to follow up their occlusal feature in the permanent dentition.

Keywords: Malay children, primary dentition, malocclusion, occlusal features.

Introduction

In 1935, a study was conducted by Chapman to determine the occlusal changes in children between the age of 3 – 6 years. He described how a presentation of malocclusion at 3 years might become normal by the age of 6 years [1,2]. Vast series of studies were then conducted to assess the development of occlusion [3, 4, 5, 6].

Primary dentition serves as a template for the permanent dentition. Crowding of primary incisors are most likely to be followed by crowding of permanent incisors [5]. Bouge in 1908 suggested that if malocclusion were found in the primary dentition, there was a high probability that the similar problems could be seen in permanent dentition [6]. The data shows that malocclusion and occlusal features varies greatly between populations studied. Studies regarding occlusion in the primary dentition and its related tooth dimension have been published such as in Arab groups including Egyptian [7] and Saudi children [8, 9] followed by India [10, 11, 12]. No

*Corresponding to: Annapurny Venkiteswaran, Faculty of Dentistry, Universiti Teknologi MARA, Sungai Buloh Campus, Jalan Hospital, 47000 Sungai Buloh, Selangor, Malaysia.

Email: annapurny@uitm.edu.my

Tel: +603 61266445

such data seems to be available presently in Malaysian children.

It is important for the clinician to understand the changes that occur in the occlusion between primary dentition and permanent dentition in order to construct a treatment plan for an early orthodontic intervention ^[5]. Early recognition of potentially malocclusion in developing occlusion will help in deciding what short term or long term treatment the child will require. It is important for the clinician to refer these children with the incipient malocclusion in at the right time.

Since no record of studies pertaining to occlusal features in preschool children in Malaysia was found, a baseline study was suggested to conduct this study in Malay children. Therefore the objective of the study was to determine the different occlusal characteristic in primary dentition of 3 to 6 years old children in Malaysia and to create a preliminary database for future Malaysian researchers.

Materials and Methods

Sixty preschool children were selected comprising of 30 male and 30 female in the age group of 3 – 6 years, attending the nurseries and kindergartens at Sungai Buloh, Selangor . Convenient sampling was executed based on the sample size calculated in the available population with 95% of confidence level along with 5 as the confidence interval to select the sample and each sample was assessed for a various occlusal characteristics according Foster and Hamilton criteria ^[13] and also Kislign and Kerbs criteria ^[14] .

Ethical approval (Ref:600-RMI 5/1/6) was obtained from Faculty of Dentistry UiTM Sungai Buloh Ethics review board, University Technology of Mara. Parents or

guardian signed the informed consent form prior to dental examination of the children. The kindergarten and nursery were selected based on the location which were near and convenient to access for conducting the study. Children with mixed dentition, abnormal dentition, infraocclusion, incomplete set of primary dentition, extensive caries, and systemic disease were excluded. Out of 60 children, 13 children were excluded as they failed to fulfill the inclusion criterias.

The remaining 47 children comprising of 27 male and 20 female were selected based on having a complete set of primary dentition, no periodontal disease and medically fit fulfilling the inclusion criteria for the study from these selected schools and nursery.

The subjects were divided into 2 groups according to their gender. Proof of age and date of birth of each child was obtained from the school records and also from parents. Informed consent was taken from both, the parents and school authorities. All subjects were examined in their respective school premises under the natural day light and dental portable light for a proper illumination. Disposable mouth mirror and probe, gauze, cotton roll, ruler and caliper were used along with the floss whenever in doubt regarding the caries and space. The terminal plane relationship, canine relationship, overjet and overbite of each subjects were evaluated by using Foster and Hamilton criteria^[13] in a definite centric occlusion.

The terminal plane of molars were classified as distal step, mesial step or flush plane. Canine relationship was classified as Class I, Class II or Class III. Overjet between 0-2mm was recorded as normal, overjet above 2mm was classified as increased overjet and when maxillary incisors were lingual to the mandibular

incisors, it was classified as reversed overjet. Overbite between 10-40% was deemed normal while measurement more than 40% was classified as deep. The subject could also present with an edge to edge bite or an open bite whereby there was no measurement value for overbite.

Kisling and Kerbs criteria was applied to record the spacing in the dentition^[14]. The spaces were categorised as spacing present, teeth in contact or teeth overlapped. Primate spaces which refers to the the space between the lateral incisor and canine in the maxillary arch and the space between canine and first molar in the mandibular arch were recorded.

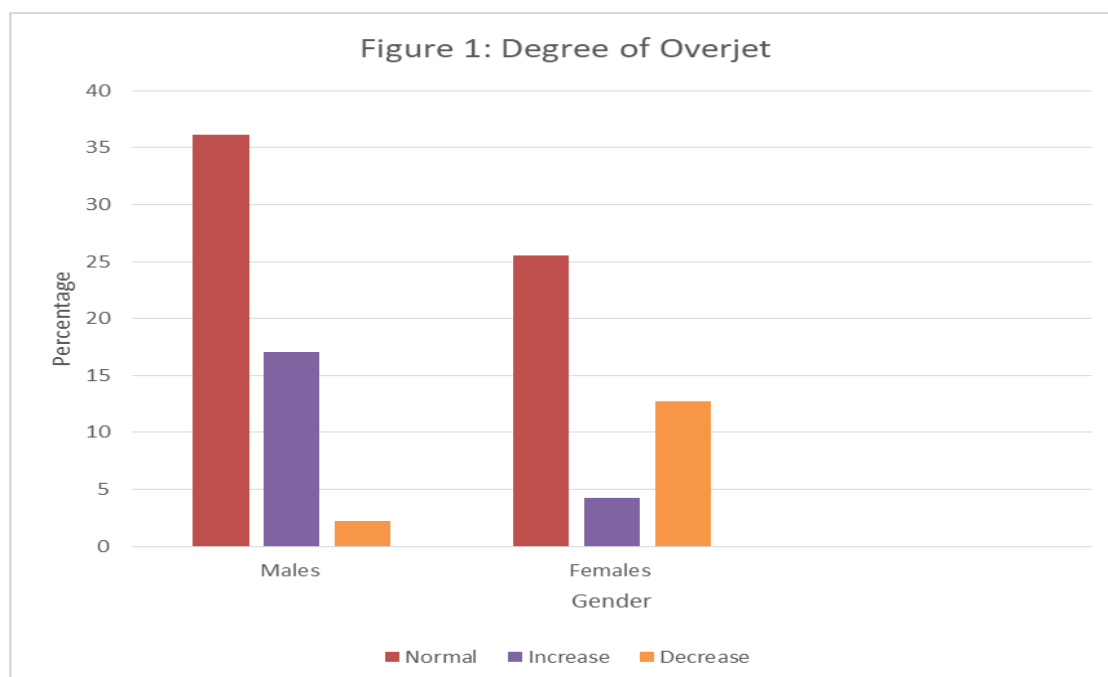
All the data collection techniques were done under a supervision and recorded in a designed data record sheet and series of photographs. Two examiners carried out the examination. Both were final year students at the Faculty of Dentistry, UiTM and they had a kappa score of 0.96 which ensured that they were calibrated for the examination and recording of data. Prevalence rates of different occlusal characteristics assessed were calculated.

Analysis done by using a statistical software, Statistical Package for Social Sciences (SPSS 23.0).

Results

The most prevalent molar relationship in the subjects were bilateral straight terminal plane with 72.34%. This was followed by bilateral mesial terminal plane which was present in 21.27% children and the least was asymmetry terminal plane which was present in 6.38% of the children. Although there was a significant difference within the sample group, there was no significant difference between gender ($p=0.447$). As for canine classification, 97.87% of the subjects showed bilateral class I relationship while the remaining presented with an asymmetrical canine relationship.

The results show that an ideal overjet can be seen as the most prevalent in both gender with a total of 61.70% followed by increased overjet with 21.28%, while remaining subjects (17.02%) had decreased overjet (Fig.1). There was no significant differences between gender in

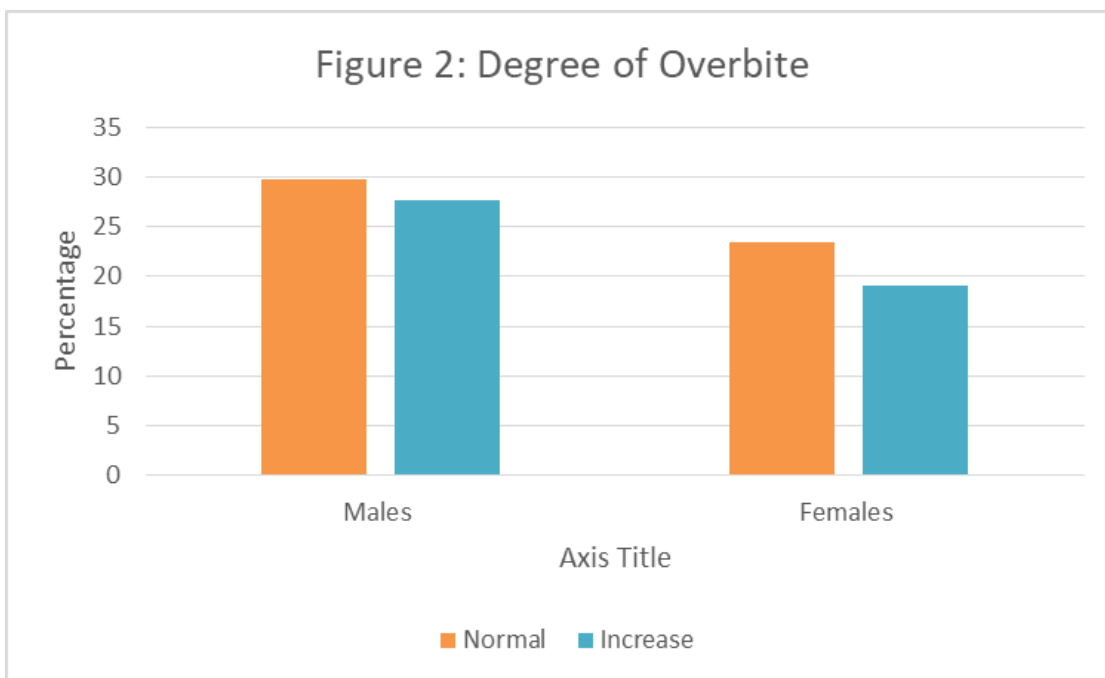


terms of overjet ($p=0.063$).

The evaluation of overbite has shown that 53.19% of the children had an ideal overbite while the remaining children recorded an increase in overbite. None of the patients had decreased overbite (Fig.2). There was no significant differences between gender in terms of overbite ($p=0.831$)

Primate spaces were present in both dental arches and as shown in Table 1, the mean value is higher for the space present in maxilla. Majority of the children of the

children had primate space in the maxilla only. None of the subjects presented with primate space solely in mandible. All the subjects who had spacing in the maxillary arch ($n=42$) had spacing of more than 1mm. As for the mandibular arch, 27.27% of the subjects had spacing less than 1mm while the remaining had spacing between 1 – 2.3mm. Overall, 10.64% of the subjects did not have any spacing and the teeth were in contact, none of the teeth were overlapped. Table 2 shows a summary of findings in all the categories investigated.



Arch	n	Mean±s.d(mm)
Maxilla	42	2.92±1.558
Mandible	11	1.591±0.701

Table 1 : Primate space value according to archwise analysis

Occlusal Features	Prevalence (%)
Terminal plane relationship	Straight Mesial Step Asymmetry
	72.34 21.27 6.38
Canine Relationship	Class I Asymmetry
	97.73 2.13
Overjet	Normal Increased Decreased
	61.70 21.28 17.02
Overbite	Normal Increased
	53.19 46.81
Primate Spaces	Maxillary Arch Mandibular Arch
	89.36 23.40

Table 2 : Prevalence of selective occlusal features

Discussion

The development of an occlusion in a child is of great interest as it allows us to predict a future malocclusion which may require early intervention such as interceptive orthodontics. The complete set of primary dentition is established by age of three years and lasts until age six whereby the first permanent teeth begin to erupt^[5].

The straight terminal plane in the primary dentition is the most prevalent followed by mesial and distal terminal plane^[3, 16, 17] and this was evident in this study as well. A straight terminal plane on primary second molars is found to be associated to a future Class I or Class II molar relationship^[19, 20].

Bishara et al (1988)^[21] found in his study that in cases with a mesial step of 2mm or more in the primary dentition, almost 70% of them progress to Class I. Mesial step was desirable because it would permit a normal occlusion of permanent molar^[10,15].

In terms of canine relationship, previous studies conducted in a different populations showed bilateral Class I canine relationship

was most prominent^[22, 23, 24, 25]. Similar result observed in this study with 97.87% having a bilateral Class I relationship. This is in contrast with a study found in Finnish children that shows higher prevalence 52.4% of Class II canine relationship, Class I with 46.1% followed by Class III with 1.5%^[26]. Assessing both primary canine and molar relationship can be a diagnostic aid to predict the changes in occlusal relationship in permanent dentition^[26].

Based on the findings of this study, 61.70% of the subjects had an ideal overjet and this is in agreement with studies done among Saudi Arabian and Chinese children^[9,23]. Interestingly, Foster and Hamilton(1969) revealed that increased overjet was seen in 72% of 2 - 3 year old British children^[27].

This study revealed that 53.19% children had an ideal overbite. This is lower than the value reported by Farsi & Salama (1996) where 76% of their subjects presented with an ideal overbite^[9].

Results obtained in our study showed that maxillary primate space was present in

89.36% of the subjects while only maxilla In comparison with spacing in mandible (distal to canine) with 23.4% of the subjects had mandibular primate space. It is widely accepted that there might be low chances for permanent teeth to have crowding if the primary dentition erupted in an arch with spaces^[29, 30, 31, 32, 33]. Majority of our children demonstrated spaced arch which would lead to a favourable permanent occlusion.

Conclusion

Majority of the Malay children in the present study have shown favourable occlusal features. Significant results were obtained in terms of terminal plane, canine relationship and ideal overjet. However, due to a very small sample size in our study no definitive outcomes can be suggested. A further longitudinal studies need to be conducted to follow the developing occlusion in these childrens if possible until all the permanent teeth are present.

References

1. Chapman H. The normal dental arch and its changes from birth to adult. *British Dental Journal* 1935; 58: 201–229.
2. Madhuri V, Chandrasekhar R, Vinay C. Occlusal Characteristics and Spacing in Primary Dentition: A Gender Comparative Cross-Sectional Study. 2014;1-7.
3. Baume LJ. Physiological tooth migration and its significance for the development of occlusion. The biogenetic course of the deciduous dentition. *Journal of Dental Research* 1950; 29: 123–132.
4. Bonnar EME. Aspects of the transition from the deciduous to the permanent dentition. *Dental Practitioner*. 1960; 11:59.
5. Leighton BC. The early signs of malocclusion. *European Orthodontic Society* 1969, pp. 353 - 365.
6. Bouge EA. Some Results from Orthodontia on Deciduous Teeth. 1908. *JAMA*, 267-269.
7. Abu A, Qudeimat MA. Occlusion and tooth/arch dimensions in the primary dentition of preschool Jordanian children. *International Journal of Paediatric Dentistry*. 2003; 13: 230–239.
8. Kaufman A, Koyoumdjisky E. Normal occlusal patterns in the deciduous dentition in preschool children in Israel. *Journal of Dental Research* 1967; 46: 478–482.
9. Farsi NM, Salama FS. Characteristics of primary dentition occlusion in a group of Saudi children. *International Journal of Paediatric Dentistry* 1996;6: 253–259.
10. Nanda RS, Khan I, Anand R. Age changes in the occlusal pattern of deciduous dentition. *J Dent Res*. 1973;52:221-24.
11. Khan R, Singh N, Govil S, Tandon S. Occlusion and occlusal characteristics of primary dentition in North Indian children of East Lucknow region. *Eur Arch Paediatr Dent* 2014; 15:293-299.
12. Bhat SS, Rao HTA, Hegde KS, Kumar BSK. Characteristic of Primary Dentition Occlusion in Preschool children : An Epidemiological Study. *Int J ClinPediatr Dent*. 20125(2):93-97.
13. Foster TD and Hamilton MC. Occlusion in the primary dentition. *British Dental Journal*. 1969;126(2):76–79.
14. Kislign E and Krebs G. Patterns of

- occlusion in 3 year old Danish children. *Community Dentistry and Oral Epidemiology*. 1976;4(4):152–159.
15. Dutra ALT, Berto PM, Vieira LDS, and Toledo OAD. Longitudinal changes in the molar relationship from primary to permanent dentition. *Consci centiae Saude*.2009; 8:171–176.
 16. Otuyemi OD, Sote EO, Isiekwe MC, Jones SP. Occlusal relationships and spacing or crowding of teeth in the dentitions of 3–4-year-old Nigerian children. *International Journal of Paediatric Dentistry* 1997; 7: 155–160.
 17. El-Nofely A, Sadek L, Soliman N. Spacing in the human deciduous dentition in relation to tooth size and dental arch size. *Archives of Oral Biology*1989; 34: 437–441.
 18. Yilmaz Y, Urbuz YG, Sims S, Dalmis A. Primary canine and molar relationships in centric occlusion in three to six year-old Turkish children: a cross-sectional study. *Journal of Contemporary Dental Practice*.2006: 7 (3):59–66.
 19. Mahmoodian J, Afshar H, Hadjhashem A. Determination of primate Space on 4 to 5 years old children of Tehran's Kindergarten in 2000. *Journal of Dentistry (Tehran, Iran)*.2004;1(1):21–26.
 20. Johannsdottir B, Wisth PJ, Magnusson TE. Prevalence of malocclusion in 6 year old Icelandic children. *Acta Odontol Scand*. 1997;55:398-402.
 21. Bishara SE, Hoppens BJ, Jakobsen JR, Kohout FJ. Changes in the molar relationship between the deciduous and permanent dentitions: a longitudinal study. *Am J Orthod Dentofacial Orthop*. 1988;93:19-28.
 22. Keski-Nisula K, Lehto R, Lusa V, Varrela J. Occurrence of malocclusion and need of orthodontic treatment in early mixed dentition. *The American Journal of Orthodontics and Dentofacial Orthopedics*. 2003; 124 (6):631–638.
 23. Imudom S. Occlusal characteristics of 5-year-old southern Chinese children. *European Journal of Orthodontics*. 1994;16:456–457.
 24. Carlsen DB, Meredith HV. Biologic variation in the selected relationship of opposing posterior teeth. *Angle Orthod*. 1960;30:162-73.
 25. Ngan P, Fields H. Orthodontic diagnosis and treatment planning in the primary dentition. *ASDC J Dent Child*. 1995;62:25-33
 26. Ravn JJ. Longitudinal study of occlusion in the primary dentition in 3 to 7 years old children. *Scand J. Dent. Res*. 1980;88:165-170.
 27. Foster TD, Hamilton MC, Lavelle CLB. Dentition and dental arch dimensions in British children at age 2.5–3 years. *Archives of Oral Biology* 1969; 14: 1031–1040.
 28. Boyko DJ. The incidence of primary spaces in fifty 3-year-old children of Burlington study. *American Journal of Orthodontics*1968; 54: 462–465.
 29. Sillman JH. Serial study of occlusion Birth to Ten years old age. *Am. J. Orthod*, 1948;34:969-879.
 30. Townsend GC, Brown T. Heritability of permanent tooth size. *American Journal of Physiology and Anthropology*1978; 49: 497–504.
 31. Friel S. The development of ideal occlusion of the gum pad and the teeth. *American Journal of Orthodontics*1954; 40: 196–227.

32. Clinch LM. A longitudinal study of the mesiodistal crown diameters of the deciduous teeth and their permanent successors. Transactions of the European Orthodontic Society 1963; 39: 202–215.
33. Moorrees CFA, Thomsen SO, Jensen E, Yen PK. Mesiodistal crown diameters of the deciduous and permanent teeth in individuals. Journal of Dental Research 1957; 36: 39-47