

Case Report

# Unsplinted Metal Reinforced Implant Retained Overdenture for An Edentulous Arch

Nur Hafizah Kamar Affendi <sup>\*1</sup> Nor Faharina Bt Abd Hamid<sup>1</sup>

<sup>1</sup> Center of Restorative Dentistry Studies, Faculty of Dentistry, Sungai Buloh Campus, Universiti Teknologi MARA.

DOI: <https://doi.org/10.24191/cos.v4i0.17513>

---

## Abstract

**Objective:** This article discuss a clinical case of implant retained overdenture as a predictable and effective treatment for completely edentulous arch.

**Material and method:** A patient with an edentulous maxilla and periodontically compromised teeth in the mandible was treated using a specific surgical and prosthodontic protocol. Patient was followed for 12 months postloading.

**Result:** The implants are still osseointegrated and able to maintain healthy mucosa surrounding implants. The patient have verbally indicated that she is satisfied with the design that gives her comfort and function.

**Conclusions:** It appears that unsplinted freestanding implants can be used as a predictable treatment for edentulous arch.

**Keywords:** Overdenture, implant retained, locator

---

## Introduction

Traditionally, complete dentures were the only available treatment option for restoring edentulous arch before the introduction of endosseous implant. With dental implants, patients can choose to have implant retained overdenture and implant supported fixed dental prostheses either with screw or cement retained. The introduction of maxillary implant retained overdenture have the advantage of

providing facial scaffolding in patient with loss of lip support, assist in resolving adverse ridge discrepancies and most importantly creating a palatal contour for better phonation and function.' . However, maxillary implant retained overdenture have not been as successful as other mandibular implant-retained prostheses. Therefore, to establish evidence-based practice and minimize failure rates, protocols have been documented for maxillary implant retained overdenture by placing a minimum of four implants with wide anteroposterior distribution for optimal support. In addition, accurate impression material and technique is crucial to produce accurate master cast and

---

\*Correspondence to: Nur Hafizah Kamar Affendi, Centre of Restorative Dentistry Studies, Faculty of Dentistry, Universiti Teknologi MARA, 47000 Sungai Buloh, Selangor, Malaysia  
Email: [hafizah\\_kamar@uitm.edu.my](mailto:hafizah_kamar@uitm.edu.my)  
Tel: +603-61266593

minimizing error during prostheses fabrication. To date, refined technique and products with better predictability are now available and enable clinicians to transfer the attachment overdentures. Therefore, this case report will illustrate the steps taken for overdenture construction on maxillary and mandibular arch.

**Material and method**

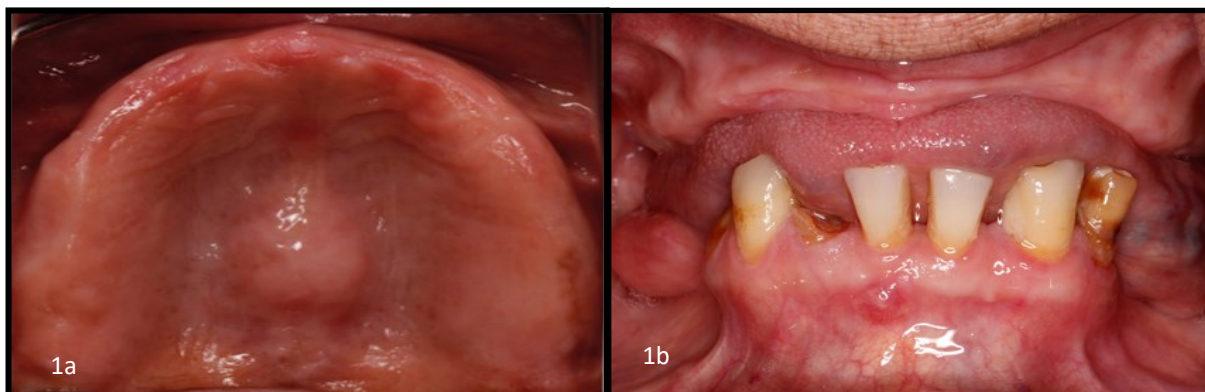
**Diagnosis and Treatment Planning**

A female patient presented with complains of loose denture. She does not like wearing adhesive that make her vomits. She had no medical history about systemic health problems. Upon thorough intraoral examination and radiographic investigations revealed an edentulous arch on the maxilla and periodontally compromised existing mandibular teeth. (Fig. 1)

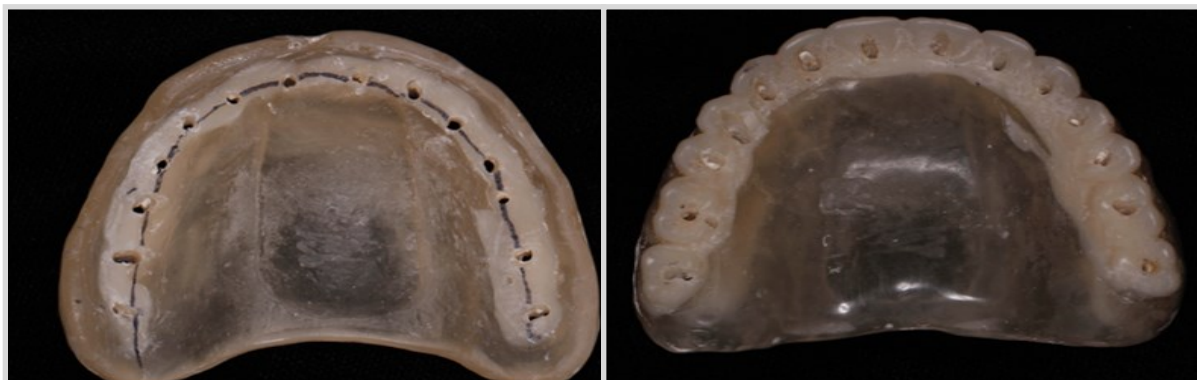
After further discussion with patient, treatment options were given to her either to restore with implant supported fixed dental prostheses or implant retained overdenture. Since a removable implant overdenture may circumvent extensive and costly augmentation procedure in fixed, she chooses to have an implant-retained overdenture on both her arch. Existing denture was duplicated and converted into radiographic and surgical guide (Fig 2). Holes are made on central fossa of tooth to assist in implant placement and give illustration on tooth position during cone beam scanning. A thorough cone beam scan analysis was done and patient has adequate bone height and width for implant placement.

**Preprosthetic/Surgical Phase**

Preoperatively, patient was prescribed with 2g amoxicillin. Postoperatively, patient took



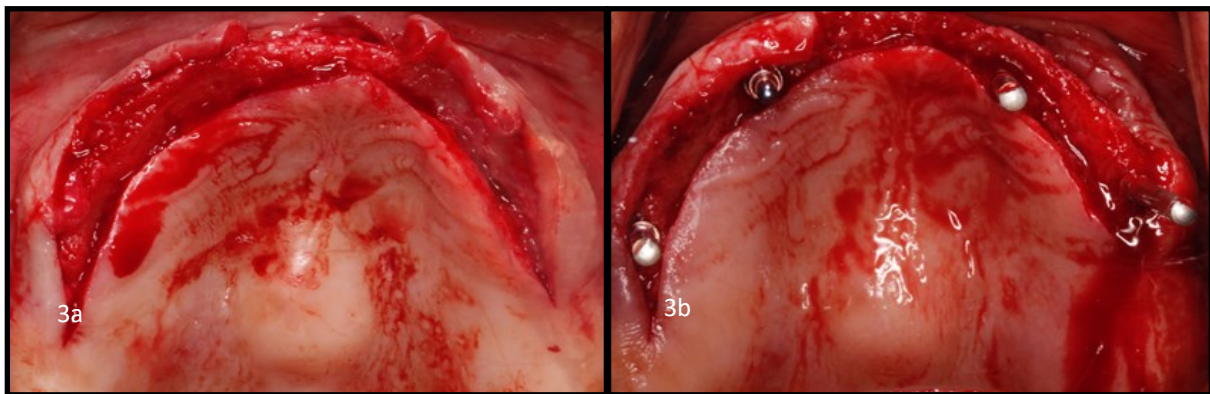
**Figure 1a,1b:** Edentulous maxilla and periodontally compromised teeth on mandible



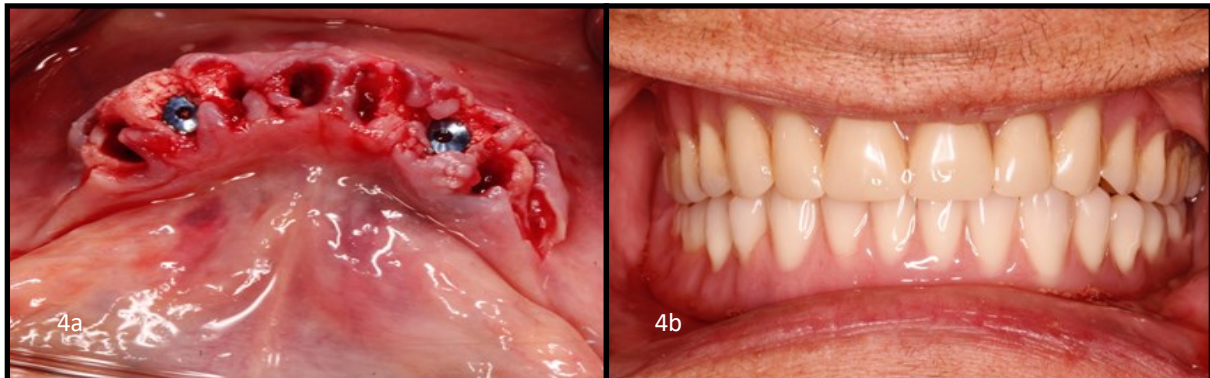
**Figure 2 :** Duplication of existing denture for radiographic and surgical guide

one 500 mg tablet of amoxicillin 3 times a day for 7 days. Full-thickness mucoperiosteal flaps were reflected. (Fig 3a) A minimum of 4 implants was placed according to radiographic guide (Fig 3b). On her mandibular arch, teeth was extracted and immediately placed with implants on canine area (Fig 4a). After the insertion, the buccal gap was grafted using Purous allograft particulate and covered

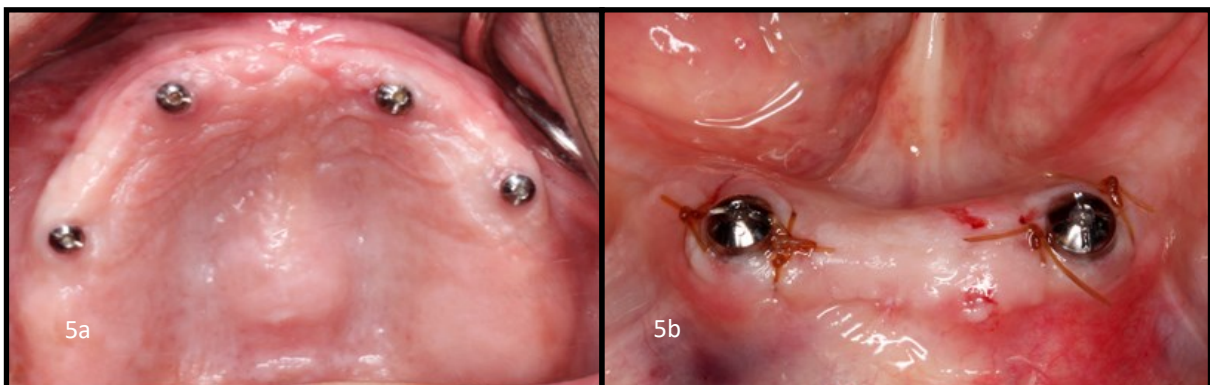
with CopiOs pericardium membrane. Patient received immediate complete denture as provisional phase to protect tissue and reduce bleeding (Fig 4b). After uneventful healing for 12 weeks, second stage surgery was performed with preservation of keratinized tissue circumferentially and healing abutment was inserted into the implants (Fig 5a,b)



**Figure 3a,3b:** Full thickness flap was raised and four implant was inserted



**Figure 4a,4b:** Extraction and immediate implant and immediate denture delivery



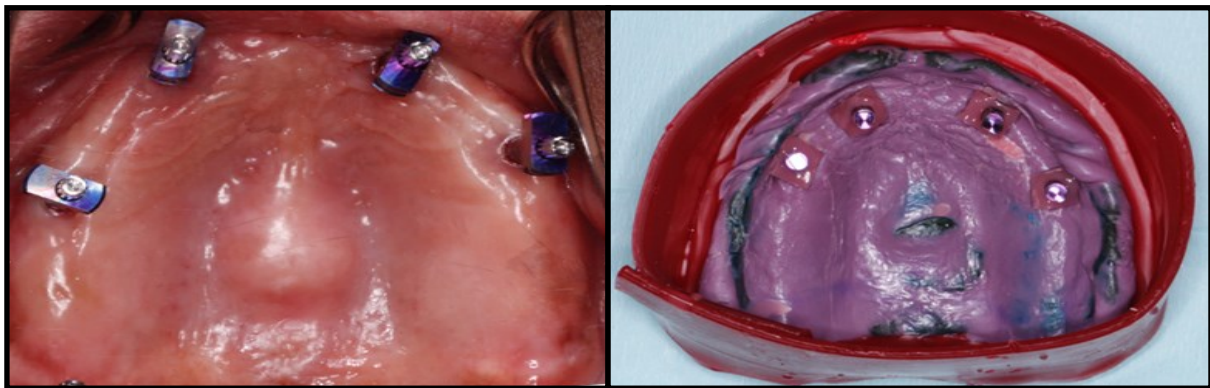
**Figure 5a,5b:** Second stage surgery on maxilla and mandible



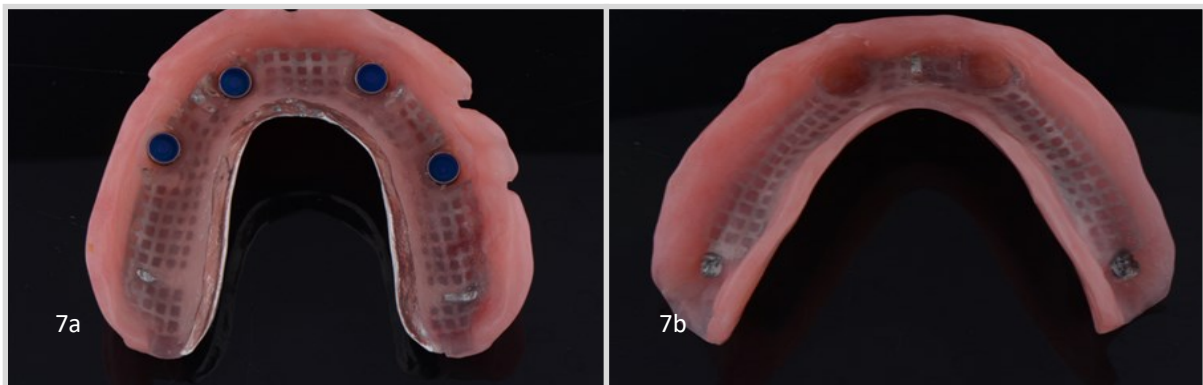
**Definitive phase**

For overdenture fabrication, steps by step approach and standard protocol were followed. Preliminary impression was taken with alginate for construction of special tray. Short impression coping was inserted and final impression taken with polyether (Fig 6a,6b). Once the working model ready, the construction of overdenture has similar steps with conventional technique. The

changes in steps occur during final processing and fabrication where it was reinforced with chromium cobalt horseshoe shape framework embedded in methyl methacrylate denture base. (Fig 7a,7b). During delivery, stud attachments or locator are torque according to manufacturer's protocol. (Fig 8a). Retentive attachments were processed into the denture base for maxilla for indirect pick-up (Fig 8b) while for

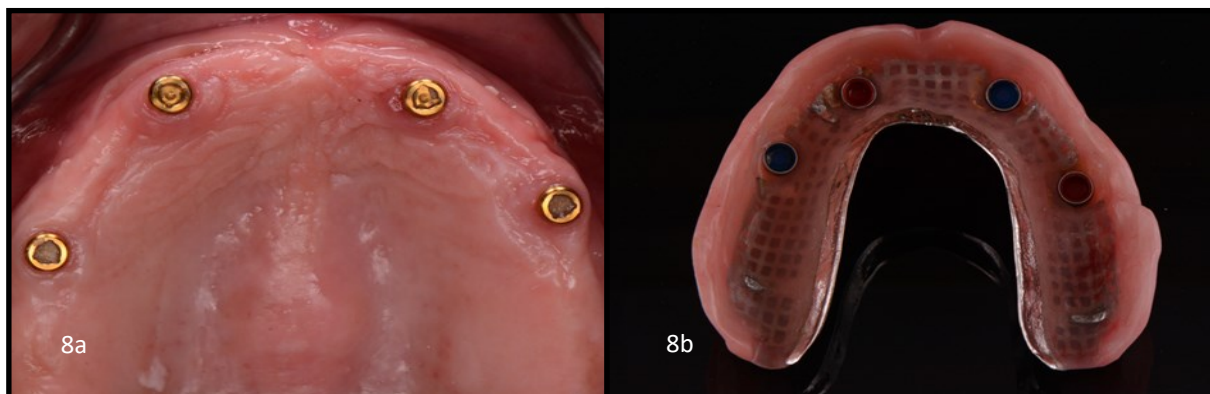


**Figure 6a,6b:** Impression coping inserted and pick up with for final impression



**Figure 7a:** Cobalt chrome reinforced overdenture on maxilla for indirect pickup

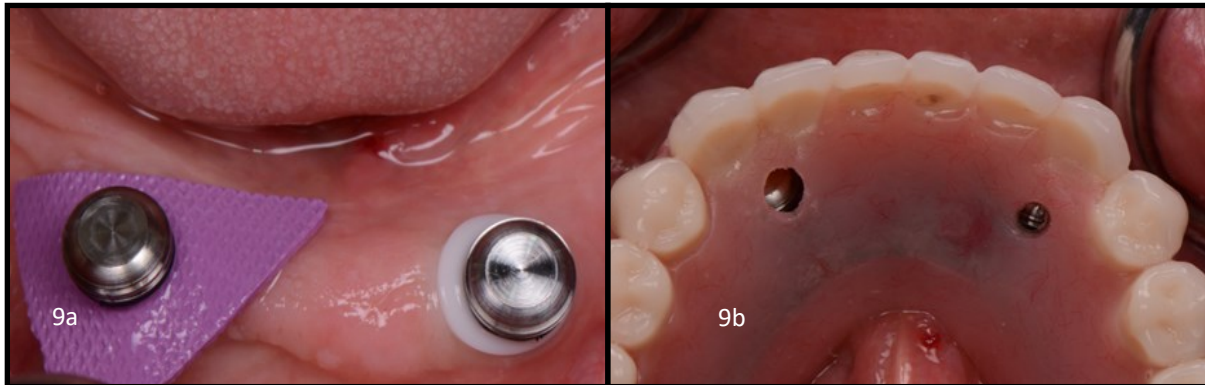
**Figure 7b:** Cobalt chrome reinforced overdenture on mandible for direct pickup. The part for pick up



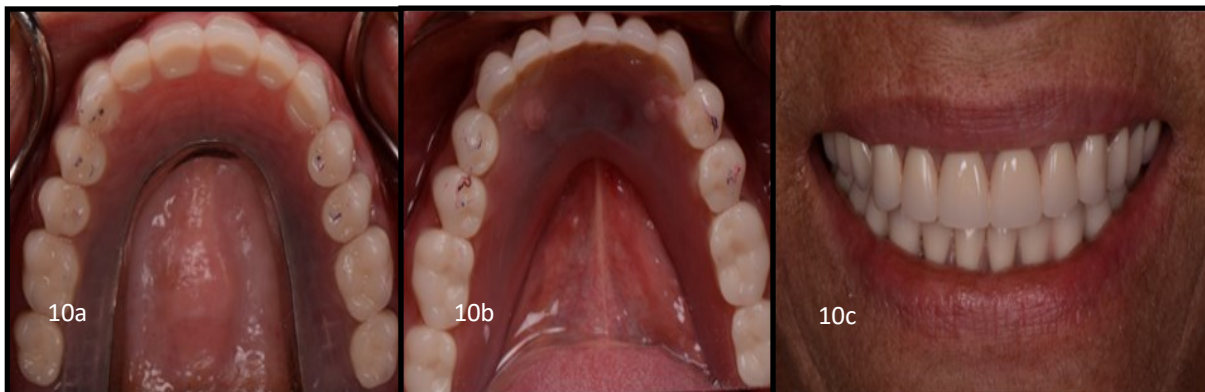
**Figure 8a,8b:** Stud attachment/locator was torque and male component (arrow) inserted into metal housing

the mandible are connected intraorally.(Fig 9a, 9b) Patient was very happy and

satisfied with her new prostheses.(Fig 10a, 10b, 10c)



**Figure 9a,9b:** Metal housing inserted directly to locator and attached to denture component and direct pick up with chairside hard reline material.



**Figure 10a,10 b,10c :** Delivery of unsplinted overdenture on both arch and satisfied patient

## Result

All implants are osseointegrated and nonmobile. The mucosa surrounding implants reveal no inflammatory lesion with probing depth less than 5 mm. In a period of 12 months, the attachment has maintained their retentive force. Patient expresses her satisfaction during transitioning from complete denture to overdenture.

## Discussion

This case report indicated as a reliable treatment options to give to patient based on suitable case selection. The usage of at least 4 textured implants with suitable length and diameter can contribute to

success and predictable treatment for maxillary overdenture. In addition, the surgical protocol with undersized osteotomies to achieved primary stability may contribute to positive outcome of implant osseointegration. For the prosthodontics protocol, the definitive overdenture base was made with metal reinforced cobalt chrome with the goal to reduce the risk of fracture or perforation. The area which implants were placed was constructed with metal freebase to facilitate trimming during chairside pick up. Currently, no publishes articles have specifically compared the performance of complete and partial coverage design. However, this palate free design may improve patient quality of life and taste reflection. With regard to the stud

attachment design, placing of the attachment may avoid multiple visits for patient and does not impart stress on precision fit as compared to bar or splinted design. Furthermore, the need to splinting impression with jig was unnecessary and simplified the procedure of overdenture fabrication.

Within the limitation of this case report which is lack of controls, further prospective controlled clinical trials with larger treatment groups will reveal the future application of this specific surgical and prosthodontic protocol for patients who are edentulous especially in the maxilla.

## Conclusion

On the basis of this study, the unsplinted implant retained overdenture can be economical and functional when compared to fixed restoration. The use of metal reinforced cobalt chrome inside acrylic base provides rigidity to prevent crack or fracture. In addition, the use of stud attachment may simplify the procedure of restoring edentulous arch and relatively easier as compared to splinted design. Lastly, the patient benefited tremendously as presented in this clinical report.

## References

1. Kronström, M., Widbom, C., & Söderfeldt, B. (2006). Patient Evaluation after Treatment with Maxillary Implant-Supported Overdentures. *Clinical implant dentistry and related research*, 8(1), 39-43.
2. Zitzmann, N. U., & Marinello, C. P. (1999). Treatment plan for restoring the edentulous maxilla with implant-supported restorations: removable overdenture versus fixed partial denture design. *The Journal of prosthetic dentistry*, 82(2), 188-196.
3. Johns, R. B., Jemt, T., Heath, M. R., Hutton, J. E., McKenna, S., McNamara, D. C., ... & Herrmann, I. (1992). A Multicenter Study of Overdentures Supported by Brånemark Implants. *International Journal of Oral & Maxillofacial Implants*, 7(4).
4. Sadowsky, S. J., & Zitzmann, N. U. (2016). Protocols for the Maxillary Implant Overdenture: A Systematic Review. *International Journal of Oral & Maxillofacial Implants*, 31.
5. Lee, H., So, J. S., Hochstedler, J. L., & Ercoli, C. (2008). The accuracy of implant impressions: a systematic review. *The Journal of prosthetic dentistry*, 100(4), 285-291.
6. Chen ST, Buser D. Clinical and esthetic outcomes of implants placed in postextraction sites. *International journal of oral & maxillofacial implants*. 2009 Oct 2;24.
7. Cavallaro Jr, J. S., & Tarnow, D. P. (2007). Unsplinted implants retaining maxillary overdentures with partial palatal coverage: report of 5 consecutive cases. *International Journal of Oral & Maxillofacial Implants*, 22(5).
8. Quirynen, M., Naert, I., & Van Steenberghe, D. (1992). Fixture design and overload influence marginal bone loss and future success in the Brånemark® system. *Clinical oral implants research*, 3(3), 104-111.
9. Slot, W., Raghoobar, G. M., Vissink, A., & Meijer, H. J. (2014). A comparison between 4 and 6 implants in the maxillary posterior region to support an

overdenture; 1-year results from a randomized controlled trial. *Clinical oral implants research*, 25(5), 560-566.

10. Al-Zubeidi, M. I., Alsabeeha, N. H., Thomson, W. M., & Payne, A. G. (2012). Patient Satisfaction with Maxillary 3-Implant Overdentures Using Different Attachment Systems Opposing Mandibular 2-Implant Overdentures. *Clinical implant dentistry and related research*, 14(s1).